



ASRA RESIDENT SECTION COMMITTEE

GUIDE TO PERIPHERAL NERVE BLOCKS

EELLAN SIVANESAN, MD // CHAD PARVUS-TEICHMANN, MD // DANIEL ABRAHAM, MD // AMY
PEARSON, MD // JASON PAWLOWSKY, DO // SARAH HENSLEY, MD // REBECCA JOHNSON, MD

UPPER EXTREMITY BLOCKS

SECTION AUTHOR:
DANIEL ABRAHAM, MD

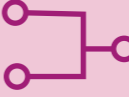

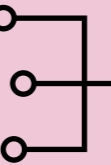

Block {Level of Block}	Distribution		Complications	Incidence & Notes	
	Nerves	Roots			
Interscalene Shoulder & Arm {TRUNKS}	Musculocutaneous	C5,6,7	Vascular / Nerve Injury		
	Axillary	C5,6	LAST		
	Radial	C5,6,7,8 T1	Phrenic N. Palsy		$\le 100\%^2$
	Median	C5,6,7,8 T1	Horner Syndrome		20% ⁴
	Ulnar (inconsistent)	C8 T1	RLN Palsy		10-20% ⁴
	Suprascapular		Intrathecal / Epidural Inj.		Rare ⁵
	Subscapular	branches off after trunks; important for shoulder innervation			
Supraclavicular Arm & Hand {DIVISIONS}	Musculocutaneous	C5,6,7	Vascular / Nerve Injury		
	Axillary	C5,6	LAST		
	Radial	C5,6,7,8 T1	Phrenic N. Palsy		50% ⁶
	Median	C5,6,7,8 T1	Pneumothorax		Rare ⁷ *
	Ulnar (inconsistent)	C8 T1			
Infraclavicular Elbow, Forearm & Hand {CORDS}	Musculocutaneous	C5,6,7	Vascular Injury		
	Axillary	C5,6	LAST		
	Radial	C5,6,7,8 T1	Nerve Injury		
	Median	C5,6,7,8 T1	Pneumothorax		Rare ⁸
	Ulnar	C8 T1			
Axillary Forearm & Hand {PERIPHERAL NERVES}	Radial	C5,6,7,8 T1	Vascular / Nerve Injury		
	Median	C5,6,7,8 T1	LAST		
	Ulnar	C8			
	Musculocutaneous**	C5,6,7			

** in order to cover the musculocutaneous n., which runs in the body of the coracobrachialis, a separate injection is required to ensure adequate blockade

* intravascular injection and pneumothorax are rare using ultrasound guidance

LOWER EXTREMITY BLOCKS

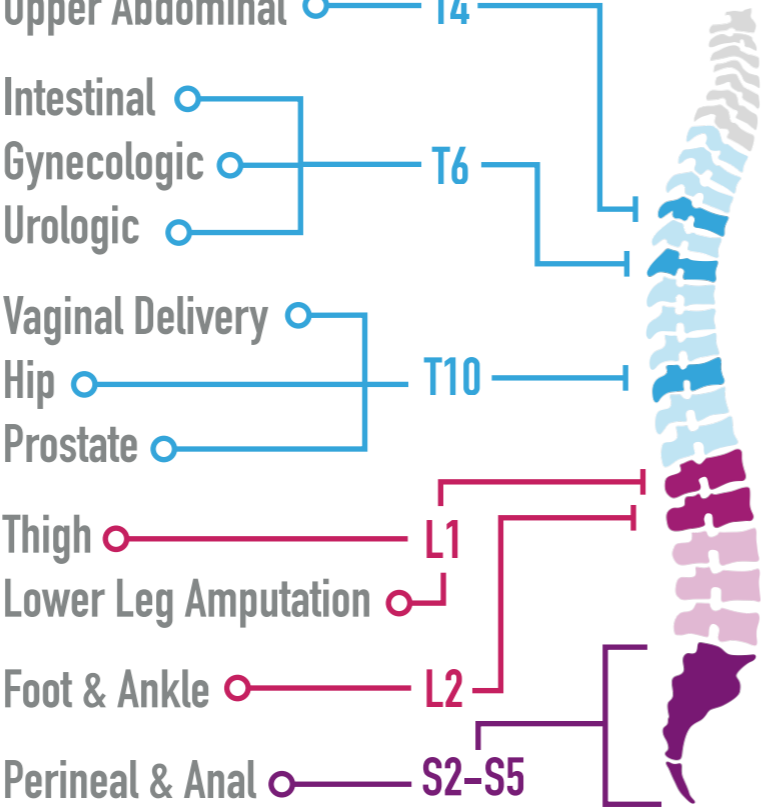
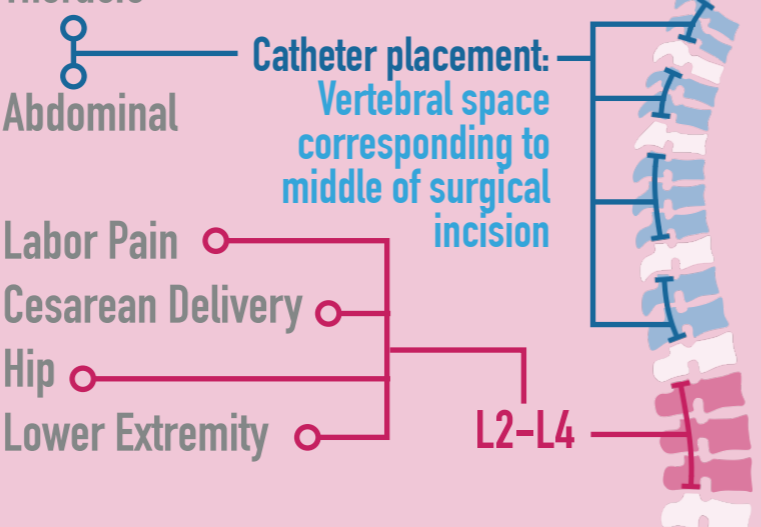
SECTION AUTHOR:
AMY PEARSON, MD

Block	Distribution		Complications	Incidence & Notes
	Nerves	Roots		
Sciatic	Sciatic	L4,5 S1,2,3	Hematoma	Rare ¹
	Tibial	L4,5 S1,2,3	Infection	<1% ²
	Common Peroneal	L4,5 S1,2	Nerve injury	Transient: 1% Permanent: <1% ²
	Posterior Femoral Cutaneous	S1,2,3	Neuropathy	Rare ³
Psoas / Lumbar Plexus	Genitofemoral	L1,2	Vascular puncture	6.6% ²
	Lateral Femoral Cutaneous	L2,3	Hematomas & LAST	More common ^{1,5-11}
	Femoral	L2,3,4	Infection, Nerve & Vascular injury	 Rare ⁴
	Obturator	L2,3,4	Epidural spread	15% ¹²
Femoral	Femoral	L2,3,4	Infection	0.5% ²  → colonization common ¹⁵
	Saphenous* * adductor canal approach	L2,3,4	Nerve injury	Transient: 0.5% Permanent: 0.2% ²
Popliteal	Sciatic	L4,5 S1,2,3	Overall	Rare ¹
	↳ Tibial	L4,5 S1,2,3	Infection	Rare ¹⁶
	↳ Common Peroneal	L4,5 S1,2	Severe Neuropathy	Rare ¹⁶  → nerve is superficial to popliteal vessels, thus hematoma and infection are rare
Ankle	Saphenous	L3,4	LAST	<1% ^{20,21}
	Posterior Tibial	L4,5 S1,2,3	Paresthesias	<1% ¹⁷⁻²⁰  → avoid excessive tourniquette pressures
	Deep Peroneal	L4,5 S1,2		
	Superficial Peroneal	L4,5 S1,2		
	Sural	S1,2		

note: avoid epinephrine 2/2 risk of tissue necrosis^{22,23}

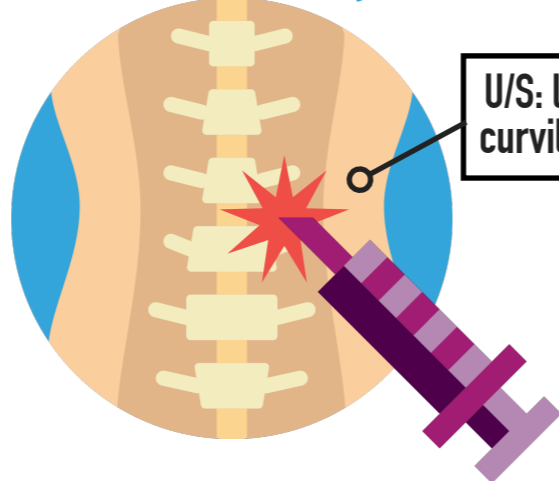
NEURAXIAL BLOCKS

SECTION AUTHOR:
JASON PAWLOWSKY, DO

Technique	Distribution	Complications	Incidence & Notes
Spinal	<p>Surgery Location Level</p> 	<p>Meningitis</p> <p>Post-dural Puncture H/A</p> <p>High Spinal Blockade Cardiovascular Collapse</p> <p>Neurologic Injury</p> <p>Spinal Hematoma Cauda Equina Syndrome</p>	<p>3.7-7.2 in 100k¹</p> <p>0.37-2.7%² → use of larger needle & cutting point vs pencil-point needle ↑ risk</p> <p>Varies</p> <p>0.025%³</p> <p>0.3%³ → including peripheral n. injuries & cauda equina syndrome</p> <p>0.00063%⁴</p> <p>1 in 550k⁵</p>
	<p>Thoracic</p> <p>Abdominal</p> <p>Labor Pain</p> <p>Cesarean Delivery</p> <p>Hip</p> <p>Lower Extremity</p> <p>Catheter placement: Vertebral space corresponding to middle of surgical incision</p> 	<p>Meningitis</p> <p>Post-dural Puncture H/A Subdural Puncture</p> <p>Spinal Cord / Nerve Injury</p> <p>Cauda Equina Syndrome</p> <p>Epidural Abscess</p> <p>Epidural Hematoma</p> <p>Minor Back Pain</p>	<p>5 in 450k⁶</p> <p>Varies</p> <p>0.82%⁷ → may result in high spinal</p> <p>0.03-0.1%⁴</p> <p>1 in 170k⁵</p> <p>0.2-83 in 100k¹</p> <p>26 in 450k⁶</p> <p>20-30%⁴</p>
Epidural			

PARAVERTEBRAL BLOCKS

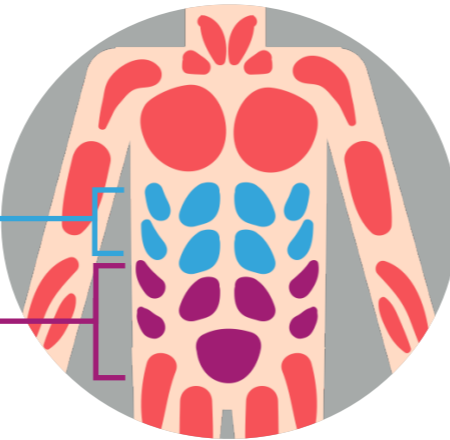
SECTION AUTHOR:
EELLAN SIVANESAN, MD

Block	Distribution	Complications	Incidence & Notes
Paravertebral Thoracotomy, Breast & Open Abdominal Surgeries	Ipsilateral dermatomal distribution based on level & volume of injection 	Block Failure Vascular Puncture Hematoma Hypotension LAST Epidural / Intrathecal Spread Pleural Puncture Pneumothorax	9% ¹ 6.8% ² 2.4% ² 0.47-4% ^{1,2} 0.23% ¹ 0-1.28% ¹⁻³ → medially-directed needle ↑ risk of epidural or subarachnoid entry 0-0.8% ^{1,2} 0-0.64% ¹⁻³

↓ paravertebral muscle pain w/ smaller gauge needles

TAP: TRANSVERSUS ABDOMINIS PLANE

SECTION AUTHOR:
SARAH HENSLEY, MD

Block	Distribution	Complications	Incidence & Notes
Transversus Abdominis Plane Multimodal Component of Analgesia for Major Abdominal Surgeries	Dermatomal Coverage: Subcostal Approach: T6-T9 Classic Approach: T10-L1 	Bleeding Infection Nerve injury LAST Liver Injury	similarly rare incidence as w/ other regional blocks ¹ ↑ risk in parturients; consider ↓ dosing ² ↑ concern 2/2 relatively large volume (~20cc) LA injected ^{1,2} 2 case reports (1 landmark, 1 U/S) ³

References: Upper Extremity Blocks

- 1 Kroll DA, Caplan RA, Posner K, et al: Nerve Injury associated with anesthesia. *Anesthesiology* 1990; 73: 202–207.
- 2 Urmey WF, Talts KH, Sharrock NE: One hundred percent incidence of hemidiaphragmatic paresis associated with interscalene brachial plexus anesthesia as diagnosed by ultrasonography. *Anesth Analg* 1991; 72(4): 498
- 3 Sanchez M, Malhotra N, Lin L, et al. End-stage pulmonary disease and brachial plexus regional anesthesia: their implications on perioperative pulmonary function. *Semin Cardiothoracic Vasc Anesth* 2012; 16(1): 59–64
- 4 Vester-Andersen T, Christiansen C, et al. Interscalene brachial plexus block: area of analgesia, complications, and blood concentrations of local anesthetics. *Acta Anaesthesiol Scand* 1981; 25(2): 81–4.
- 5 Dutton RP, Eckhardt WF, et al. Total spinal anesthesia after interscalene blockade of the brachial plexus. *Anesthesiology* 1994; 80(4): 939–41.
- 6 Neal J, Moore J, Kopacz D, et al: Quantitative analysis of respiratory, motor, and sensory function after supraclavicular block. *Anesth Analg* 1998; 86: 1239–1244
- 7 Brand L, Papper EM, et al. A comparison of supraclavicular and axillary techniques for brachial plexus blocks. *Anesthesiology* 1961; 22: 226
- 8 Borgeat A, Ekatodramis G, et al. An evaluation of the infraclavicular block via a modified approach to the Raj technique. *Anesth Analg* 2001; 93(2): 436–41

References: Lower Extremity Blocks

- 1 Hadzic A, New York School of Regional Anesthesia. *Textbook of regional anesthesia and acute pain management*. Second edition. ed. New York: McGraw-Hill Education; 2017.
- 2 Wiegel M, Gottschaldt U, Hennebach R, Hirschberg T, Reske A. Complications and adverse effects associated with continuous peripheral nerve blocks in orthopedic patients. *Anesth Analg*. 2007;104(6):1578–1582, table of contents.
- 3 Brull R, McCartney CJ, Chan VW, El-Beheiry H. Neurological complications after regional anesthesia: contemporary estimates of risk. *Anesth Analg*. 2007;104(4):965–974.
- 4 Kinghorn K, Ellinas H, Barboi AC, Dolinski SY. Case scenario: nerve injury after knee arthroplasty and sciatic nerve block. *Anesthesiology*. 2012;116(4):918–923.
- 5 Klein SM, DErcole F, Greengrass RA, Warner DS. Enoxaparin associated with psoas hematoma and lumbar plexopathy after lumbar plexus block. *Anesthesiology*. 1997;87(6):1576–1579.
- 6 Hsu DT. Delayed retroperitoneal haematoma after failed lumbar plexus block. *Brit J Anaesth*. 2005;94(3):395–395.
- 7 Blumenthal S, Ekatodramis G, Borgeat A. Ropivacaine plasma concentrations are similar during continuous lumbar plexus blockade using two techniques: pharmacokinetics or pharmacodynamics? *Can J Anaesth*. 2004;51(8):851; author reply 851–852.

References: Lower Extremity Blocks (cont)

- 8 Aveline C. Delayed retroperitoneal haematoma after failed lumbar plexus block. *Brit J Anaesth.* 2005;94(3):395–396.
- 9 Aida S, Takahashi H, Shimoji K. Renal subcapsular hematoma after lumbar plexus block. *Anesthesiology.* 1996;84(2):452–455.
- 10 Mullanu C, Gaillat F, Scemama F, Thibault S, Lavand'homme P, Auffray JP. Acute toxicity of local anesthetic ropivacaine and mepivacaine during a combined lumbar plexus and sciatic block for hip surgery. *Acta Anaesthesiol Belg.* 2002;53(3):221–223.
- 11 Huet O, Eyrolle LJ, Mazoit JX, Ozier YM. Cardiac arrest after injection of ropivacaine for posterior lumbar plexus blockade. *Anesthesiology.* 2003;99(6):1451–1453.
- 12 Molina Monleon I, Asensio Romero I, Barrio Mataix J, Lopez Sanchez F, Peris Agudo V, Garcia Ferrando V. [Epidural anesthesia after posterior lumbar plexus block]. *Rev Esp Anesthesiol Reanim.* 2005;52(1):55–56.
- 13 Auroy Y, Benhamou D, Bargues L, et al. Major complications of regional anesthesia in France: The SOS Regional Anesthesia Hotline Service. *Anesthesiology.* 2002;97(5):1274–1280.
- 14 Capdevila X, Pirat P, Bringuier S, et al. Continuous peripheral nerve blocks in hospital wards after orthopedic surgery: a multicenter prospective analysis of the quality of postoperative analgesia and complications in 1,416 patients. *Anesthesiology.* 2005;103(5):1035–1045.
- 15 Cuvillon P, Ripart J, Lalourcey L, et al. The continuous femoral nerve block catheter for postoperative analgesia: Bacterial colonization, infectious rate and adverse effects. *Anesthesia and Analgesia.* 2001;93(4):1045–1049.
- 16 Compere V, Rey N, Baert O, et al. Major complications after 400 continuous popliteal sciatic nerve blocks for post-operative analgesia. *Acta Anaesthesiol Scand.* 2009;53(3):339–345.
- 17 Needoff M, Radford P, Costigan P. Local anesthesia for postoperative pain relief after foot surgery: a prospective clinical trial. *Foot Ankle Int.* 1995;16(1):11–13.
- 18 Reinhart DJ, Wang W, Stagg KS, et al. Postoperative analgesia after peripheral nerve block for podiatric surgery: clinical efficacy and chemical stability of lidocaine alone versus lidocaine plus clonidine. *Anesth Analg.* 1996;83(4):760–765.
- 19 Sarrafian SK, Ibrahim IN, Breihan JH. Ankle-foot peripheral nerve block for mid and forefoot surgery. *Foot Ankle.* 1983;4(2):86–90.
- 20 Frederic A, Bouchon Y. [Analgesia in surgery of the foot. Apropos of 1373 patients]. *Cah Anesthesiol.* 1996;44(2):115–118.
- 21 Myerson MS, Ruland CM, Allon SM. Regional anesthesia for foot and ankle surgery. *Foot Ankle.* 1992;13(5):282–288.
- 22 Roth RD. Utilization of epinephrine-containing anesthetic solutions in the toes. *J Am Podiatry Assoc.* 1981;71(4):189–199.
- 23 Hardy JD, Rhoads JE. Rhoads' textbook of surgery : principles and practice. 5th ed. Philadelphia: Lippincott; 1977.

References: Neuraxial Blocks

- 1 Schulz–Stübner, S., J. M. Pottinger, S. A. Coffin, and L. A. Herwaldt. "Nosocomial Infections and Infection Control in Regional Anesthesia." *Acta Anaesthesiologica Scandinavica* 52.8 (2008): 1144–157.
- 2 Gaiser, Robert. "Postdural Puncture Headache." *Current Opinion in Anaesthesiology* 19.3 (2006): 249–53.
- 3 Auroy, Yves, Dan Benhamou, Laurent Barges, Claude Ecoffey, Bruno Falissard, Frédéric Mercier, Hervé Bouaziz, and Kamran Samii. "Major Complications of Regional Anesthesia in France." *Anesthesiology* 97.5 (2002): 1274–280.
- 4 Hadzic, Admir. *Textbook of Regional Anesthesia and Acute Pain Management*. New York: McGraw–Hill, Medical Pub. Division, 2007.
- 5 Aromaa, U., M. Lahdensuu, and D. A. Cozanicis. "Severe Complications Associated with Epidural and Spinal Anaesthesias in Finland 1987–1993 A Study Based on Patient Insurance Claims." *Acta Anaesthesiologica Scandinavica* 41.4 (1997): 445–52.
- 6 Moen, Vibeke, Nils Dahlgren, and Lars Irestedt. "Severe Neurological Complications after Central Neuraxial Blockades in Sweden 1990–1999." *Anesthesiology* 101.4 (2004): 950–59.
- 7 Lubenow, Timothy, Elisa Keh–Wong, Kathy Kristof, Olga Ivankovich, and Anthony D. Ivankovich. "Inadvertent Subdural Injection." *Anesthesia & Analgesia* 67.2 (1988)

References: Paravertebral Blocks

- 1 Pace MM, Sharma B, Anderson–Dam J, Fleischmann K, Warren L, Stefanovich P. *Ultrasound–Guided Thoracic Paravertebral Blockade: A Retrospective Study of the Incidence of Complications*. Anesthesia and analgesia. 2016.
- 2 Naja Z, Lönnqvist PA. Somatic paravertebral nerve blockade incidence of failed block and complications. *Anaesthesia*. 2001;56(12):1181–1201.
- 3 Coveney E, Wertz CR, Greengrass R, et al. Use of paravertebral block anesthesia in the surgical management of breast cancer: experience in 156 cases. *Annals of surgery*. 1998;227(4):496.

References: Transversus Abdominis Plane Blocks

- 1 Lissauer J, Mancuso K, Merritt C, Prabhakar A, Kaye AD, Urman RD. Evolution of the transversus abdominis plane block and its role in postoperative analgesia. *Best Pract Res Clin Anaesthesiol*. 2014;28(2):117–26.
- 2 Griffiths, J. D., et al. "Symptomatic local anaesthetic toxicity and plasma ropivacaine concentrations after transversus abdominis plane block for Caesarean section." *British journal of anaesthesia* 110.6 (2013): 996–1000.
- 3 Young MJ, Gorlin AW, Modest VE, Quraishi SA. Clinical implications of the transversus abdominis plane block in adults. *Anesthesiol Res Pract*. 2012;2012:731645.

THIS GUIDE WAS A COLLABORATIVE EFFORT
OF THE ASRA RESIDENT SECTION COMMITTEE
EDUCATION COMMITTEE 2016

EELLAN SIVANESAN, MD
AMY PEARSON, MD

CHAD PARVUS-TEICHMANN, MD
JASON PAWLOWSKY, DO

DANIEL ABRAHAM, MD
SARAH HENSLEY, MD

WITH SPECIAL THANKS TO FACULTY MENTOR **REBECCA JOHNSON, MD**



TO LEARN MORE ABOUT ASRA, JOIN AS A RESIDENT / FELLOW MEMBER, OR APPLY TO
JOIN THE RESIDENT SECTION COMMITTEE, PLEASE VISIT WWW.ASRA.COM/RESIDENTS